

Computer tomographic and radiographic changes in the temporomandibular joints of two young adults with occlusal asymmetry, treated with the Herbst appliance

Hans Ulrik Paulsen* and Agnete Karle**

*Departments of Orthodontics, Copenhagen Municipal Dental Health Service and Royal Dental College, Aarhus University and **Department of Radiology I, Bispebjerg University Hospital, Copenhagen, Denmark

SUMMARY Two young patients, one female and one male, with asymmetric occlusal deviation and extreme Angle Class II division 1 malocclusions were treated with the Herbst appliance after cessation of endochondral growth (union of the radius epiphysis). During treatment, computer tomographic (CT) scanning and orthopantomograms of the temporomandibular joints (TMJs) revealed, as a result of bone modelling, asymmetrical new bone formation as a double contour on the distocranial part of the condyles. The treatment results were followed for more than 2 years and the new bone was found to be stable.

Introduction

The Herbst appliance (Herbst, 1910, 1922, 1934, 1936; Pancherz and Hägg, 1985) is a fixed functional appliance that continuously maintains the mandible in a protruded position during treatment. The appliance has become a reliable treatment option for patients with retrognathic mandibles and the treatment effects have been described in previous investigations (Herbst, 1910, 1922, 1934, 1936; Wieslander, 1984, 1993; Pancherz and Hägg, 1985; Hägg and Pancherz, 1988; Pancherz and Hansen, 1988; Bakke and Paulsen, 1989; Hansen *et al.*, 1990, 1991, 1997; Hägg, 1992; Hansen, 1992; Hansen and Pancherz, 1992; Paulsen *et al.*, 1995, 1999a,b; Sidhu *et al.*, 1995; Aelbers and Dermaut, 1996; Dermaut and Aelbers, 1996; Ruf and Pancherz, 1996, 1998; Paulsen, 1997). The described treatment effects have been concerned with groups of patients with normal endochondral growth to adulthood.

The aim of the present study was to investigate morphological changes in the temporomandibular joints (TMJs) of two patients in adulthood after cessation of endochondral growth (union of the radius epiphysis) with an asymmetric sagittal

molar occlusion, treated with the Herbst appliance, and followed for 2 years. Changes in the TMJs during Herbst treatment were registered on computer tomographic (CT) scans and orthopantomograms as described by Paulsen *et al.* (1995).

Subjects and methods

Two young adults, one female and one male, both 20 years of age after cessation of endochondral growth (union of the radius epiphysis) when the Herbst appliance was inserted, were chosen from a consecutive sample of 300 patients with Angle Class II division 1 malocclusions, treated with the Herbst appliance in the period of late puberty to early adult. Previous orthodontic treatment had failed due to lack of co-operation during puberty. The patients presented with mild mandibular asymmetry, the female to the left and the male to the right. The sagittal molar occlusion for the female was a full unit distal on the left side and a half unit distal on the right side, and opposite for the male. The female's maxilla showed a narrow V-form and crowding of the left side, with the second premolars in crossbite. Both patients had insufficient lip closure with lip dysfunction

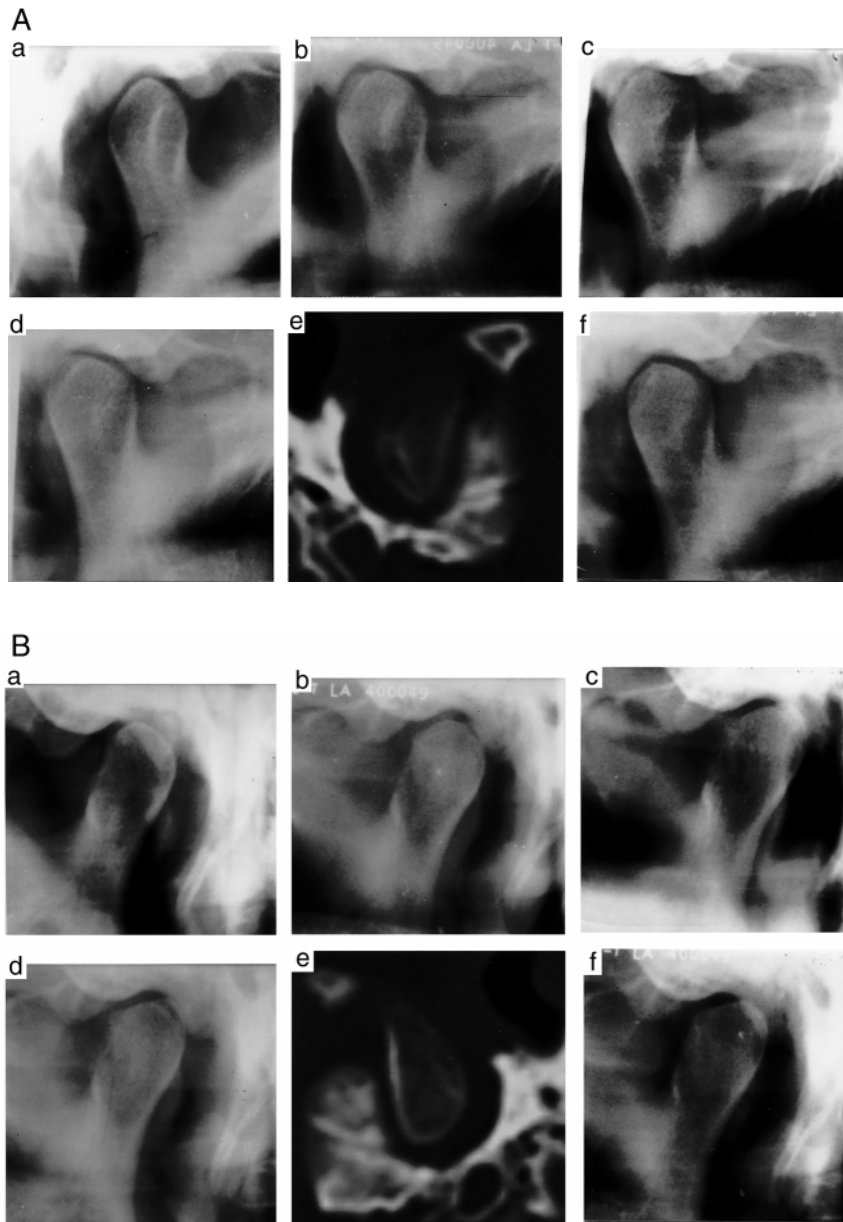


Figure 1 Radiographs and axial CT scan showing the effect on the morphology of (A) the right and (B) left condylar processes in a young female treated with the Herbst appliance at adulthood. (a) Pre-treatment. (b) Three months. (c) Six months. (d) Radiograph and (e) axial CT scan, both after 10 months of treatment. (f) Six months post-treatment. The orthopantomogram and CT were taken with a 90-degree difference. Note the change in shape of the cranioposterior part of the condylar process and the double contour with two cortical layers (b–e). The original cranioposterior part is the distinct inner contour, while the weak outer layer is the borderline of the new adaptive bone (modelling). In the period of post-treatment the outer contour changed to become distinct and the inner contour to be indefinite (slow remodelling). Skeletal maturity assessed according to Helm *et al.* (1971), a–f: Ru. Height measured without shoes to the nearest 0.5 cm. (a) 179.2; (d–e) 181; (f) 180.2.

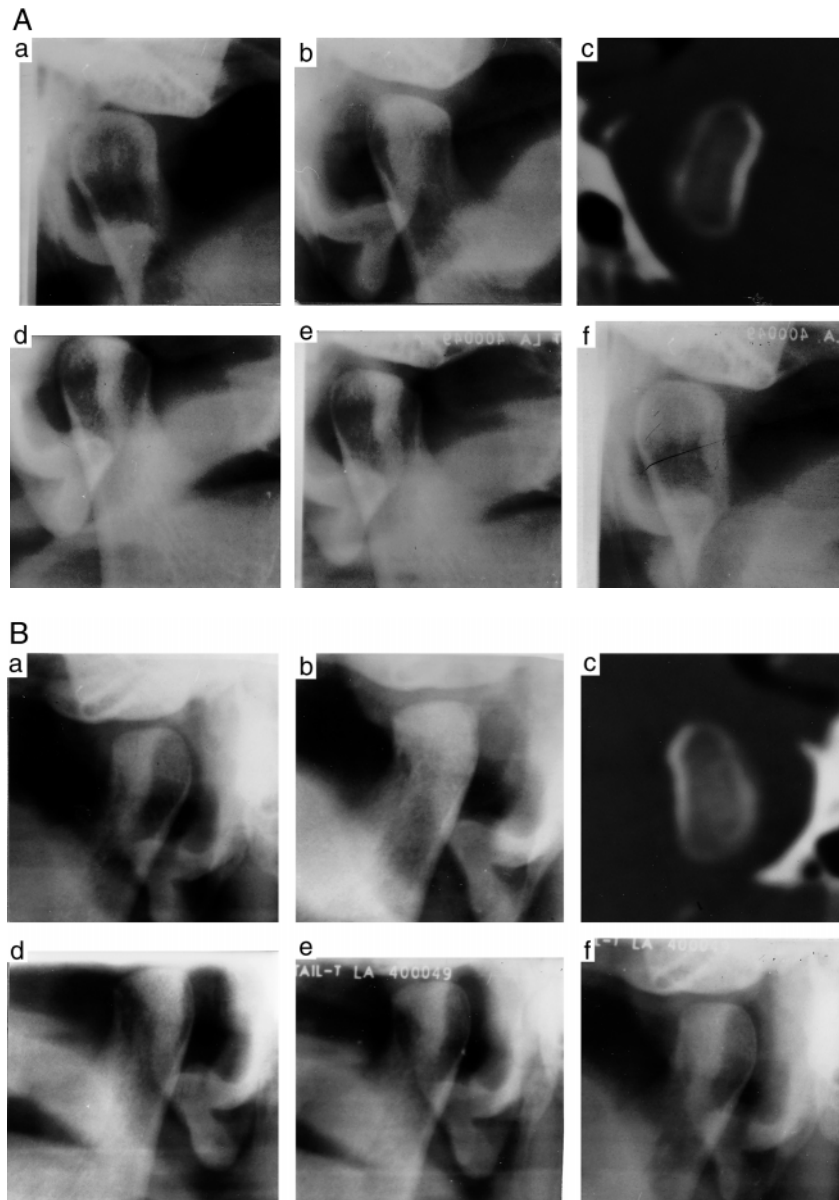


Figure 2 Radiographs and axial CT scan showing the effect on the morphology of (A) the right and (B) left condylar processes in a young male treated with the Herbst appliance at adulthood. (a) Pre-treatment. (b) Four months. (c) Axial CT scan and (d) radiograph, taken after 6 months of treatment. Post-treatment: (e) immediately after and (f) 1 year later. Note the change in shape of the cranioposterior part of the condylar process and the double contour with two cortical layers (b–d). The original (modelling). In the post-treatment period the outer contour has changed to become distinct and the inner contour to be indefinite (e) or disappeared (f) remodelling. Skeletal maturity assessed according to Helm *et al.* (1971), a–f: Ru. Height measured without shoes to the nearest 0.5 cm. A: 182.6; C–R 182; E: 182; F: 183.

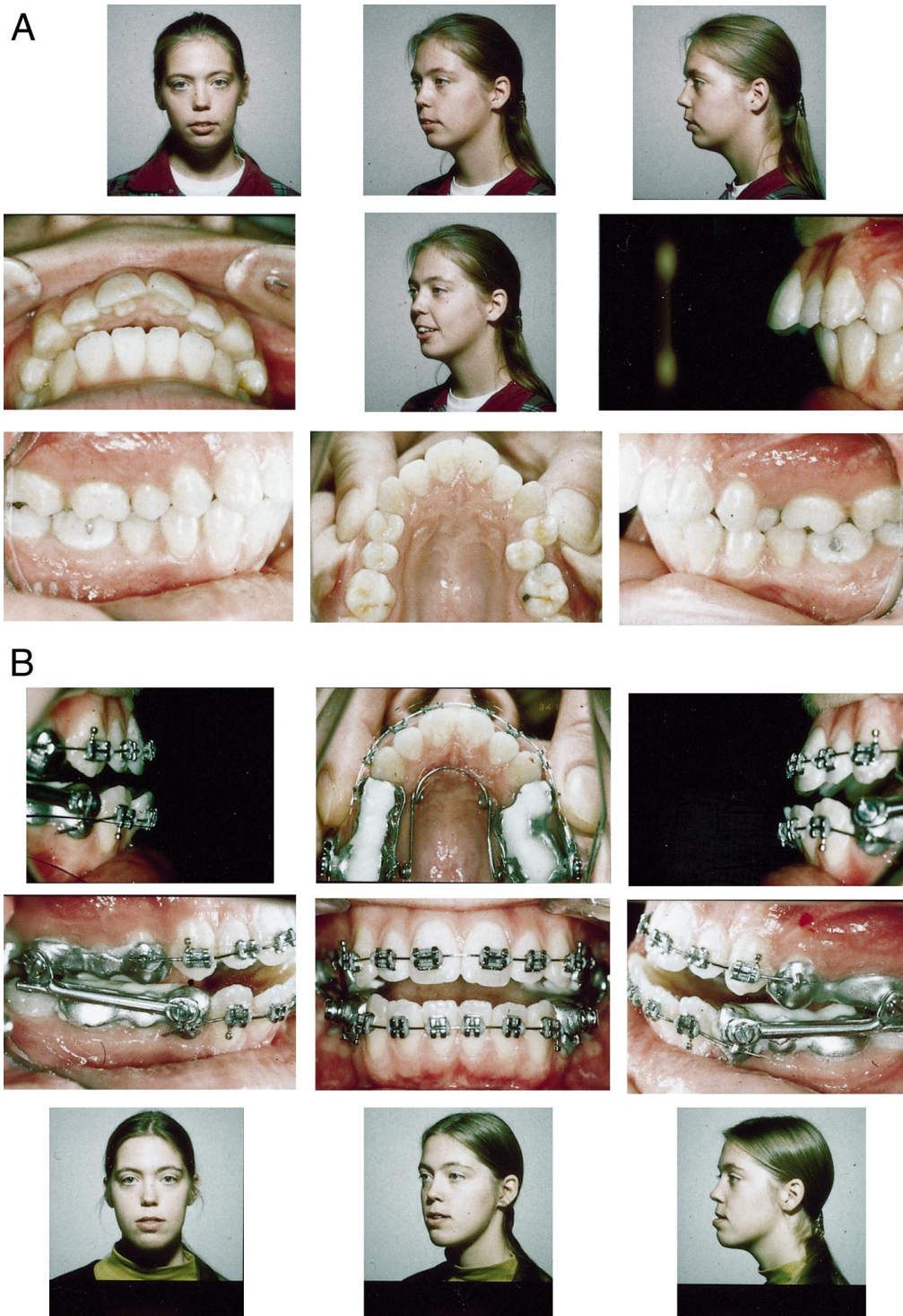


Figure 3 The female subject (A) before treatment with crowding in the maxilla, (B) Herbst appliance inserted with glass-ionomer cement, and (C) after treatment. Note the space gain in the maxilla.

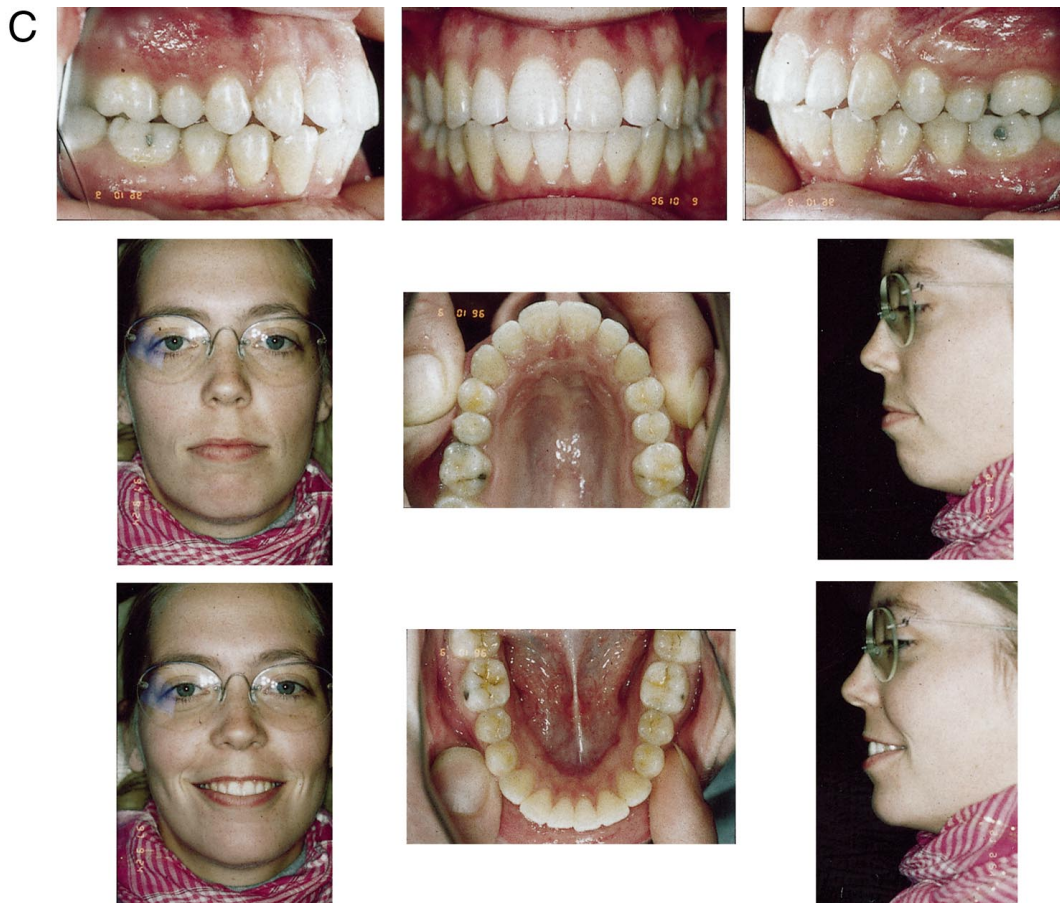


Figure 3 continued

proclining the maxillary incisors and forcing the mandible in to a distal position. Morphological analysis before treatment showed retrognathic mandibles, low mandibular plane angulation, and normal facial height. There were no symptoms or signs of craniomandibular disorders.

Treatment

The Herbst appliance was a cast chrome-cobalt type with ball hinge telescopes parallel to the occlusal plane (Roskilde Orto-Teknik™, Roskilde, Denmark). The mandibles were moved to an edge to edge contact. After 3 months the telescopes were extended by 3 mm producing a

reverse overjet of 0.5 mm. Ten months after insertion, the appliance was removed. A positioner was inserted to be used for 2 years after treatment, to safeguard stability beyond expected termination of the endochondral growth (measured by union of the radius epiphysis and no changes in stature height; Paulsen *et al.*, 1995, 1999a).

Recordings

Treatment effects on the TMJs were assessed by CT scans and orthopantomograms taken before, during and after Herbst treatment. The CT scans were taken in an axial direction

(Paulsen *et al.*, 1995) to identify the expected treatment effect of newly formed bone. This adaptive bone formation has been assessed as the region between the double contours of the distocranial part of the condyles (Paulsen, 1997). As the CT scans involved a high degree of radiation, they were taken only on three occasions: before, during, and at the end of treatment. The orthopantomograms were obtained for the female before and during treatment at 3, 6, and 10 months (end of treatment), and after treatment at 6 months and 2 years. For the male they were obtained before and during treatment at 4, 6 and 10 months (end of treatment), and 1 and 2 years post-treatment. Recordings were obtained as described previously (Paulsen *et al.*, 1995).

Skeletal maturity was assessed according to Helm *et al.* (1971) and stature height without shoes was measured to the nearest 0.5 cm.

Findings

The orthopantomograms showed double contours of the distocranial part of the condyles during treatment, the female with approximately 3–4 mm bone thickness at the right condyle (Figure 1A), and 1–2 mm at the left condyle (Figure 1B). The changes for the male were on opposite sides (Figure 2A and B). The newly formed bone was shown by distinct inner and weak outer contours during the first months of Herbst treatment. This configuration changed in radiopacity during therapy, and at the end of treatment the inner contour was indefinite (the female) or had disappeared (the male), while the outer contour was distinct.

CT scanning showed the same changes of the condyles as described from orthopantomograms. New bone formation was shown as double contours (Figures 1e and 2c). Skeletal maturity (union of the radius epiphysis) and stature height showed cessation of endochondral growth.

The treatment effect is illustrated by clinical photographs of the young female (most affected with crowding in the maxilla), taken before, during and after treatment (with space gain in the maxilla; Figure 3).

Discussion

It has previously been shown that condylar morphology changes during Herbst treatment by bone modelling, frequently in a distocranial direction (Paulsen, 1997; Paulsen *et al.*, 1995, 1999a). With epiphyseal union of the radius, further bone growth was not expected in these patients. However, the mandible is formed through costochondral ossification and the cartilage possesses a capability for biomechanically induced adaptive growth. The membrane or the fibrocartilage at the head of the condyle can be stimulated to form new bone, even though primary endochondral growth is minimal, active, or terminated. If late endochondral growth had been stimulated during treatment, any effect was expected in the condyles of the young man, according to the sex difference. The treatment showed the same effect and amount of new condylar bone in both subjects, indicating that growth stimulation was adapted from the membrane of the fibrocartilage (Stöckli, 1971; Roskjaer, 1977; Paulsen *et al.*, 1995, 1999a,b).

The effects on condylar growth show that Herbst treatment can also normalize an asymmetrical molar occlusion in adulthood, by stimulating asymmetric, adaptive new bone growth from the fibrocartilage even though endochondral growth has ceased. The treatment effect with induced perichondral adaptive growth shown by the radiographic technique was also confirmed by the CT scans during treatment.

This clinical study showing biomechanical induced adaptive condylar growth at adulthood confirms results from a histomorphometric and scanning electron microscopy study of human condylar cartilage and bone tissue changes in relation to age, indicating growth possibilities in the condyles up to 30 years of age (Paulsen *et al.*, 1999b).

Conclusions

Herbst appliance treatment produces different responses in the TMJs of a female and a male in adulthood after cessation of endochondral growth (union of the radius epiphysis). The CT scans and orthopantomograms demonstrate that

the TMJs exhibit asymmetric, adaptive bone growth, normalizing the sagittal molar occlusion. The newly formed bone was found to be stable.

Address for correspondence

Hans Ulrik Paulsen
Department of Orthodontic
Royal Dental College
Aarhus University
Vennelyst Boulevard
DK-8000 Århus C
Denmark

Acknowledgements

This investigation was supported by the Danish Dental Association and Colgate-Palmolive A/S.

References

- Aelbers C M E, Dermaut L R 1996 Orthopedics in orthodontics: part 1. Fiction or reality—a review of the literature. *American Journal of Orthodontics and Dentofacial Orthopedics* 110: 513–519
- Bakke M, Paulsen H U 1989 Herbst treatment in late adolescence: clinical, electromyographic, kinesiographic, and radiographic analysis of one case. *European Journal of Orthodontics* 11: 397–407
- Dermaut L R, Aelbers C M F 1996 Orthopedics in orthodontics: part II. Fiction or reality. A review of the literature. *American Journal of Orthodontics and Dentofacial Orthopedics* 110: 667–671
- Hägg U 1992 Change in mandibular growth direction by means of a Herbst appliance? A case report. *American Journal of Orthodontics and Dentofacial Orthopedics* 105: 456–463
- Hägg U, Pancherz H 1988 Dentofacial orthopaedics in relation to chronological age, growth period and skeletal development. An analysis of 72 male patients with Class II division 1 malocclusion treated with the Herbst appliance. *European Journal of Orthodontics* 10: 169–176
- Hansen K 1992 Post-treatment effects of the Herbst appliance. A radiographic, clinical and biometric investigation. Thesis. *Swedish Dental Journal Supplement* 88: 1–49
- Hansen K, Pancherz H 1992 Long-term effects of Herbst treatment in relation to normal growth development: a cephalometric study. *European Journal of Orthodontics* 14: 285–295
- Hansen K, Pancherz H, Petersson A 1990 Long-term effects of the Herbst appliance on the craniomandibular system with special reference to the TMJ. *European Journal of Orthodontics* 3: 244–253
- Hansen K, Pancherz H, Hägg U 1991 Long-term effects of the Herbst appliance in relation to the treatment growth period: a cephalometric study. *European Journal of Orthodontics* 13: 471–481
- Hansen K, Koutsonas T G, Pancherz H 1997 Long-term effects of Herbst treatment on the mandibular incisor segment: a cephalometric and biometric investigation. *American Journal of Orthodontics and Dentofacial Orthopedics* 112: 92–103
- Helm S, Siersbæk-Nielsen S, Skieller V, Björk A 1971 Skeletal maturation of the hand in relation to maximum pubertal growth in body height. *Tandlægebladet* 75: 1223–1234
- Herbst E 1910 Atlas und Grundriss der Zahnärztlichen Orthopädie. Lehmann's Verlag, München
- Herbst E 1922 Atlas und Grundriss der Zahnärztlichen Orthopädie. Lehmann's Verlag, München
- Herbst E 1934 Dreissigjährige Erfahrungen mit dem Retentions-Scharnier. *Zahnärztliche Rundschau* 43: 1515–1524, 1563–1568, 1611–1616
- Herbst E 1936 Praxis des Retentionsscharniers und der automatischen Regulierung. Berlinische Verlagsanstalt GMBH, Berlin
- Pancherz H, Hägg U 1985 Dentofacial orthopedics in relation to somatic maturation. *American Journal of Orthodontics* 88: 273–287
- Pancherz H, Hansen K 1988 Mandibular anchorage in Herbst treatment. *European Journal of Orthodontics* 10: 149–164
- Paulsen H U 1997 Morphological changes of TMJ condyles of 100 patients treated with the Herbst appliance in the period of puberty to adulthood: a radiographic study. *European Journal of Orthodontics* 19: 657–668
- Paulsen H U, Karle A, Bakke M, Herskind A 1995 CT-scanning and radiographic analysis of temporomandibular joints and cephalometric analysis in a case of Herbst treatment in late puberty. *European Journal of Orthodontics* 17: 165–175
- Paulsen H U, Rabøl A, Sølvsten Sørensen S 1999a Bone scintigraphy of human temporomandibular joints during Herbst treatment: a case report. *European Journal of Orthodontics* 20: 369–374
- Paulsen H U, Thomsen J S, Hougen H P, Mosekilde Li 1999b A histomorphometric and scanning electron microscopy study of human condylar cartilage and bone tissue changes in relation to age. *Clinical Orthodontics and Research* 2: 67–78
- Roskjaer M 1977 Sutures and periosteum of growing intramembranous bone. An investigation of the nasal bone of the rabbit. Thesis, University of Nijmegen, The Netherlands
- Ruf S, Pancherz H 1996 The effect of Herbst appliance treatment on the mandibular plane angle: a cephalometric roentgenographic study. *American Journal of Orthodontics and Dentofacial Orthopedics* 110: 225–229

- Ruf S, Pancherz H 1998 Long-term effects of Herbst treatment: a clinical and MRI study. *American Journal of Orthodontics and Dentofacial Orthopedics* 114: 475–483
- Sidhu M S, Kharbanda O P, Sidu S S 1995 Cephalometric analysis of changes produced by a modified Herbst appliance in the treatment of Class II division 1 malocclusion. *British Journal of Orthodontics* 22: 1–12
- Stöckli P W 1971 Tissue reactions in temporomandibular joint resulting from anterior displacement of the mandible in the monkey. *American Journal of Orthodontics* 60: 142–155
- Wieslander L 1984 Intensive treatment of severe Class II malocclusions with a headgear-Herbst appliance in the early mixed dentition. *American Journal of Orthodontics* 86: 1–13
- Wieslander L 1993 Long-term effect of treatment with the headgear-Herbst appliance in the early mixed dentition. Stability or relapse? *American Journal of Orthodontics and Dentofacial Orthopedics* 104: 319–329